

# Efficacy of Avapritinib in Patients With Advanced Systemic Mastocytosis: Hematologic and Bone Marrow Responses From the Phase 2 Open-Label, Single-Arm, PATHFINDER Study

Poster Number  
2565

Tracy I. George, MD,<sup>1</sup> Kristin H. Karner, MD,<sup>1</sup> Karen A. Moser, MD,<sup>1</sup> Anton Rets, MD,<sup>1</sup> Michelle Fredericks, BS,<sup>2</sup> Andreas Reiter, MD,<sup>3</sup> Deepti H. Radia, MD,<sup>4</sup> Michael Deininger, MD, PhD,<sup>5</sup> Hui-Min Lin, PhD,<sup>2</sup> Jayita Sen, PhD,<sup>2</sup> Saša Dimitrijević, PhD,<sup>2</sup> Jason Gotlib, MD, MS,<sup>6</sup> Daniel J. DeAngelo, MD, PhD<sup>7</sup>

<sup>1</sup>ARUP Laboratories, Department of Pathology, University of Utah School of Medicine, Salt Lake City, UT, USA; <sup>2</sup>Blueprint Medicines Corporation, Cambridge, MA, USA; <sup>3</sup>Department of Hematology and Oncology, University Hospital Mannheim, Heidelberg University, Mannheim, Germany; <sup>4</sup>Guy's & St Thomas' NHS Foundation Trust, London, UK; <sup>5</sup>Versiti Blood Research Institute, Division of Hematology and Oncology, Medical College of Wisconsin, Milwaukee, WI, USA; <sup>6</sup>Stanford Cancer Institute, Stanford University School of Medicine, Stanford, CA, USA; <sup>7</sup>Department of Medical Oncology, Dana-Farber Cancer Institute, Boston, MA, USA

## Introduction

- Systemic mastocytosis (SM) is a mast cell (MC) neoplasm driven by the *KIT* D816V mutation in ~95% of cases, resulting in MC hyperactivation and accumulation in various organs<sup>1,2</sup>
- Diagnosis of SM includes<sup>3-7</sup>:
  - Evaluation of MC aggregates in bone marrow (BM) and extracutaneous organs
  - Atypical MC morphology
  - Expression of CD25 with or without CD2 on MCs
  - Detection of the *KIT* D816V mutation
  - Serum tryptase level of >20 ng/ml (if no associated myeloid neoplasm is present)
- In addition, expression of CD30 is observed on neoplastic MCs in patients with SM<sup>8</sup>
- Patients with advanced systemic mastocytosis (AdvSM), including mast cell leukemia (MCL), SM with an associated hematologic neoplasm (SM-AHN), and aggressive SM, have traditionally had a poor prognosis<sup>9</sup>
- Avapritinib, a highly potent and selective *KIT* D816V inhibitor, is now approved by the FDA for the treatment of adults with AdvSM based on results from the phase 1 open-label, single-arm dose escalation EXPLORER (NCT02561988) study and phase 2 open-label, single-arm PATHFINDER (NCT03580655) study<sup>10</sup>
- In EXPLORER (cut-off date May 27, 2020) and PATHFINDER (cut-off date June 23, 2020) overall response rates (ORR; defined as complete remission + complete remission with partial hematologic recovery + partial remission + clinical improvement) per modified International Working Group-Myeloproliferative Neoplasms Research and Treatment and European Competence Network on Mastocytosis (miWG-MNRT-ECNM) criteria were 75% in both studies<sup>11-13</sup>
  - In both studies, improvements in BM MC burden and patient symptoms were observed<sup>11-13</sup>
  - Responses were observed across subtypes, including SM-AHN, the most frequent subtype<sup>11-13</sup>
  - In PATHFINDER, reductions ≥50% in absolute eosinophil counts were observed in 88% of patients with baseline elevated eosinophils, and reductions of ≥50% in absolute monocyte counts were observed in 80% of patients with systemic mastocytosis with associated chronic myelomonocytic leukemia as associated hematologic neoplasm (SM-AHN CMML)<sup>12,13</sup>
- Here we report on the effect of avapritinib on MC burden, morphology, and immunohistochemistry in BM, BM cellularity and fibrosis, as well as changes in selected hematologic parameters in patients with AdvSM enrolled in the PATHFINDER study (cut-off date of April 20, 2021)

- Evaluations of morphology were performed using standard Wright-Giemsa and H&E staining, while immunohistochemistry was performed on formalin-fixed EDTA-decalcified BM sections using standard techniques for tryptase, CD117, CD25, and CD30. Staining was also performed to detect reticulin and collagen fibrosis
- Changes in BM cellularity, myelofibrosis (MF) score, collagen fibrosis grade, and osteosclerosis grade were also assessed
  - Bone marrow fibrosis grading was performed using the European Consensus grading system (MF 0-3)<sup>14</sup>; a separate grading was conducted for collagen fibrosis and osteosclerosis (Grade 0-3)<sup>15</sup>

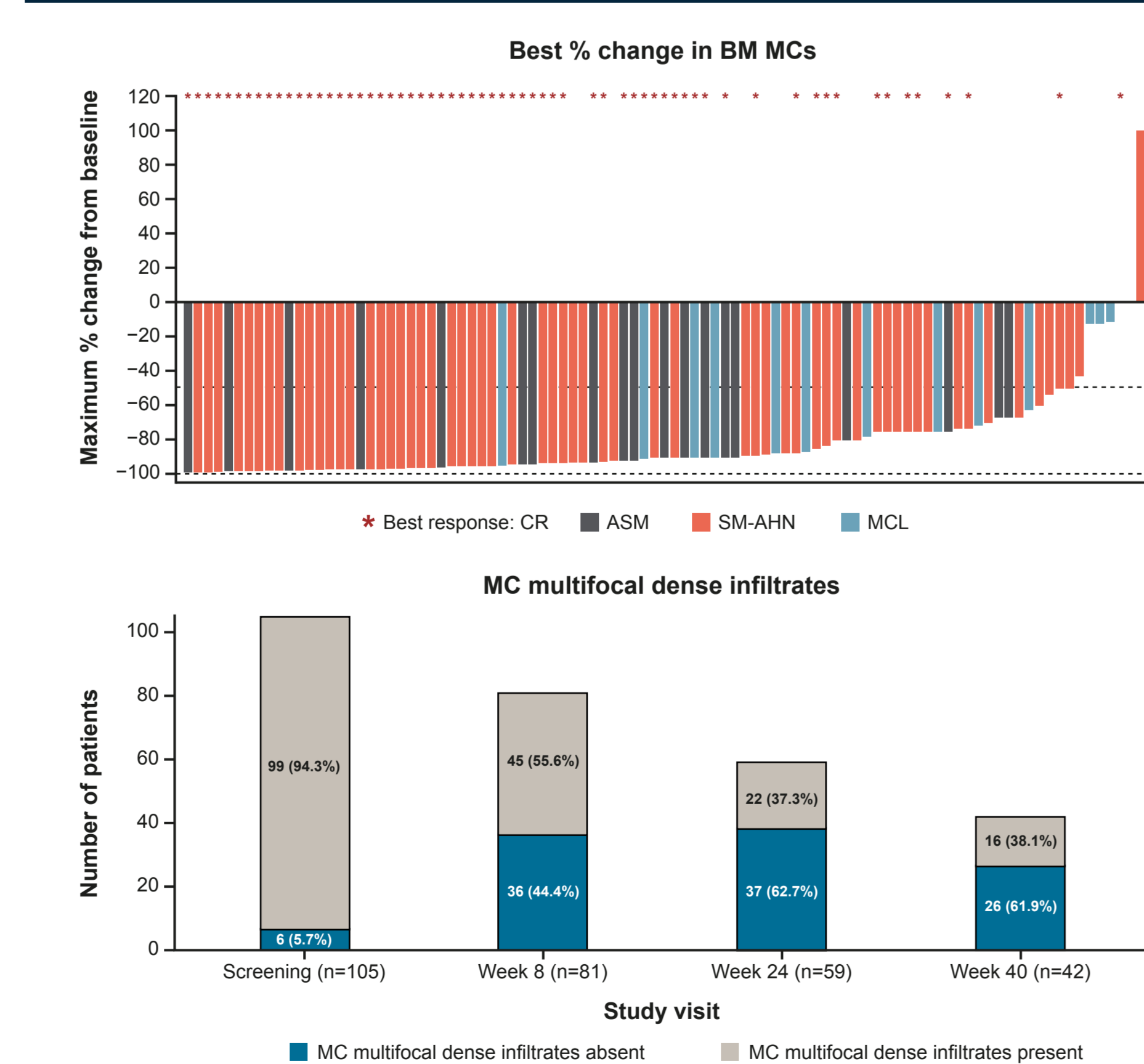
## Results

**Table 1. Baseline characteristics (N=107)**

	All doses (N=107)
Median age, years (range)	68 (31-88)
Male, n (%)	62 (57.9)
Female, n (%)	45 (42.1)
ECOG PS n (%)	
0	22 (20.6)
1	58 (54.2)
2	19 (17.8)
AdvSM subtype per central assessment, n (%)	
ASM	21 (19.6)
SM-AHN	71 (66.4)
MCL	15 (14.0)
<i>KIT</i> D816V VAF positive in blood, median % (range)	15.8 (0-47.5)
<i>KIT</i> D816V mutation positive, n (%)	103 (96.3)
<i>SRSF2/ASXL1/RUNX1</i> mutation positive, n (%)	48 (44.9)
Any prior anti-neoplastic therapy, n (%)	
Midostaurin	58 (54.2)
Ciadribine	12 (11.2)
BM biopsy MC burden, median % (range)	40 (1-95)
Serum tryptase level, median ng/mL (range)	262 (23.8-1600.0)
Spleen volume, median mL (range)	839.4 (44.2-2897.1)

AdvSM, advanced systemic mastocytosis; ASM, aggressive systemic mastocytosis; BM, bone marrow; ECOG PS, Eastern Cooperative Oncology Group Performance Status; MC, mast cell; MCL, mast cell leukemia; SM-AHN, systemic mastocytosis with associated hematologic neoplasm; VAF, variant allele fraction.

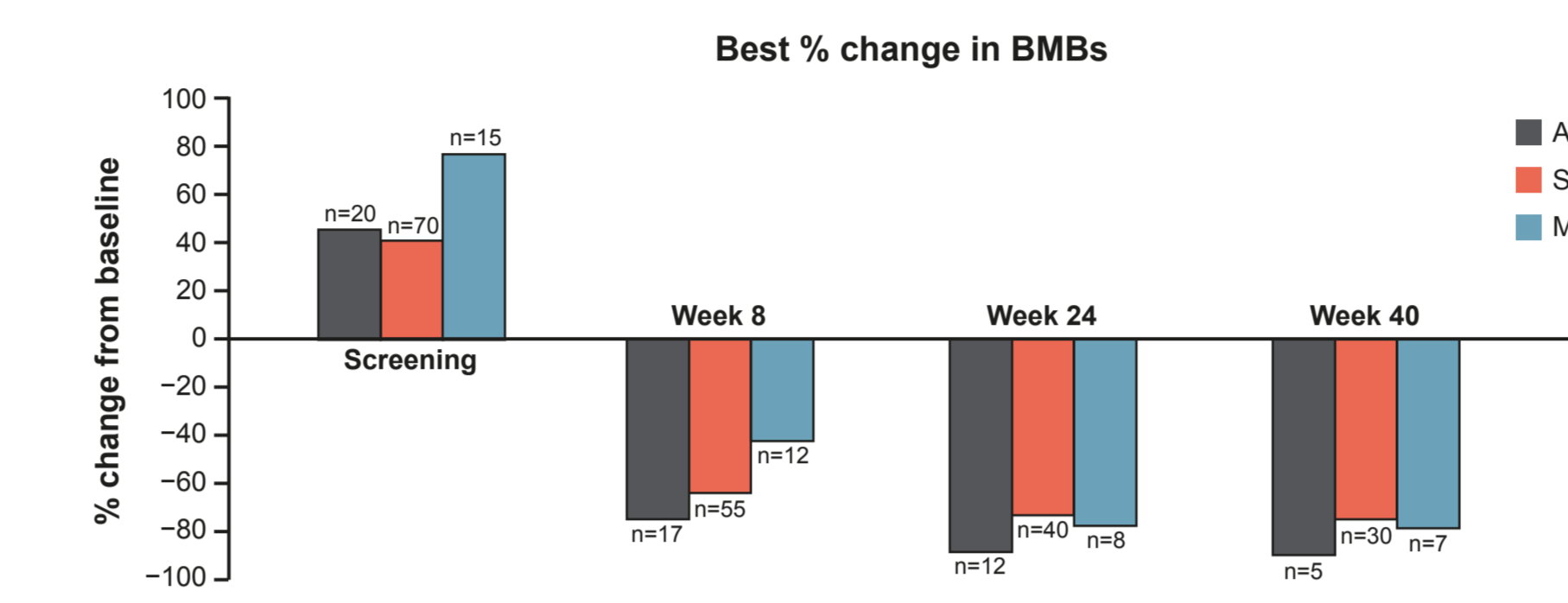
**Figure 2. Reduction of BM MC burden observed in >95% of patients with avapritinib (N=107)**



AdvSM, advanced systemic mastocytosis; BM, bone marrow; CR, complete remission; MC, mast cell.

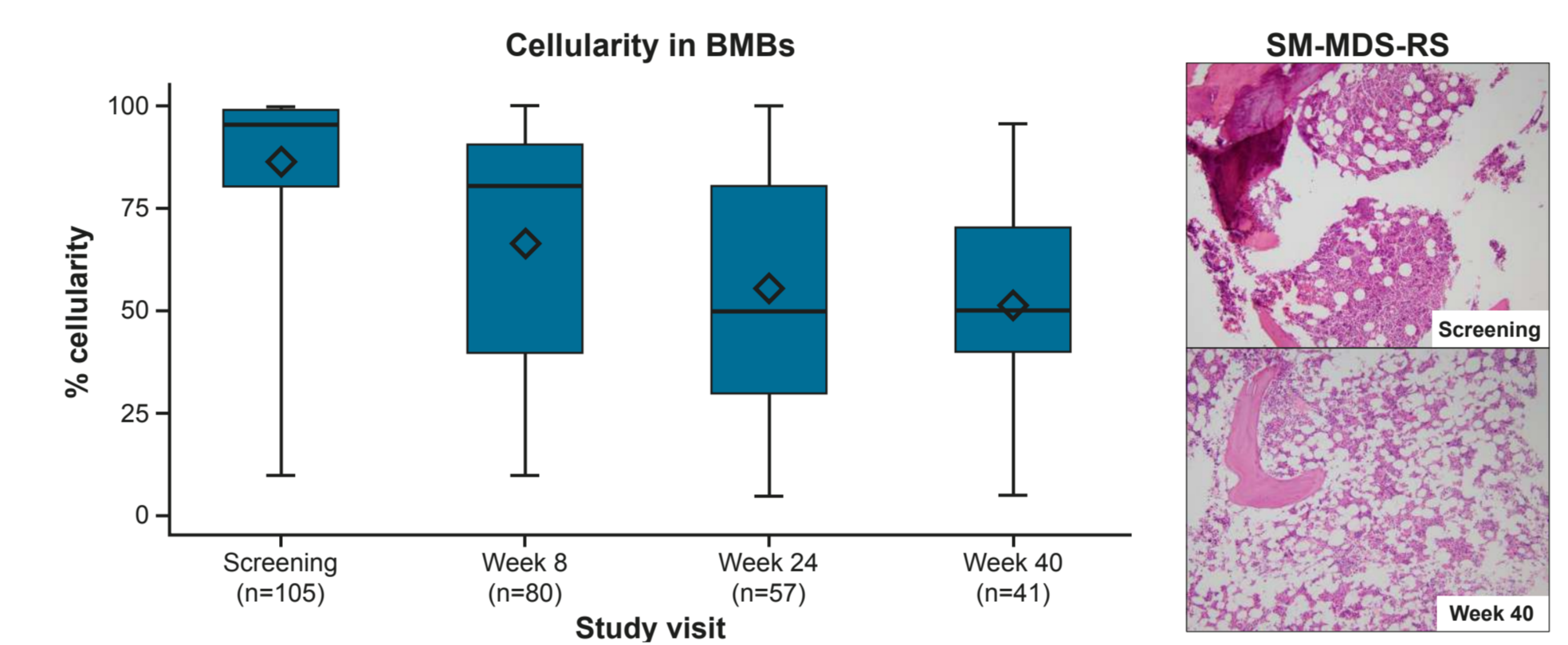
- Reductions of ≥50% from baseline in BM MCs were observed in 83.8% (88/105) of patients, and 60.0% (63/105) of patients had elimination of BM MC aggregates

**Figure 3. Reduction in mean percentage of MCs in BMs by AdvSM subtypes over time**



AdvSM, advanced systemic mastocytosis; ASM, aggressive systemic mastocytosis; BM, bone marrow; BMs, bone marrow biopsies; MC, mast cell; MCL, mast cell leukemia; SM-AHN, systemic mastocytosis with associated hematologic neoplasm.

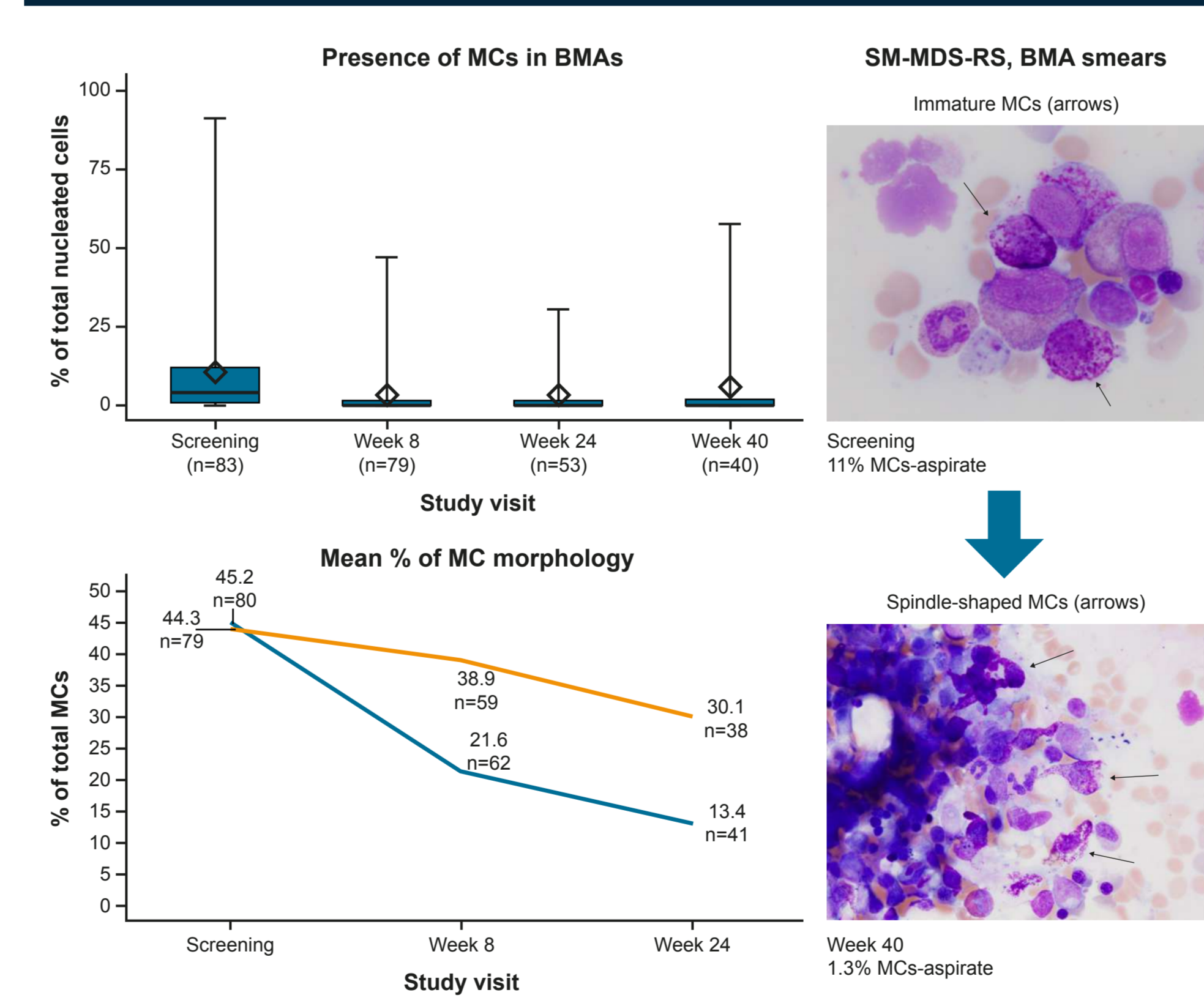
**Figure 4. Cellularity in BMs decreased with avapritinib by Weeks 8 and 24**



BMs, bone marrow biopsies; SM-MDS-RS, systemic mastocytosis-myelodysplastic syndrome-with ring sideroblasts. The box represents the middle (second and third quartile) of the data, the line within the box represents the median, the diamond represents the mean, and the end of the whiskers represents the max and min values.

- Cellularity in BMs decreased from a mean of 85.4% at screening to 66.1% at Week 8 and 55.3% by Week 24

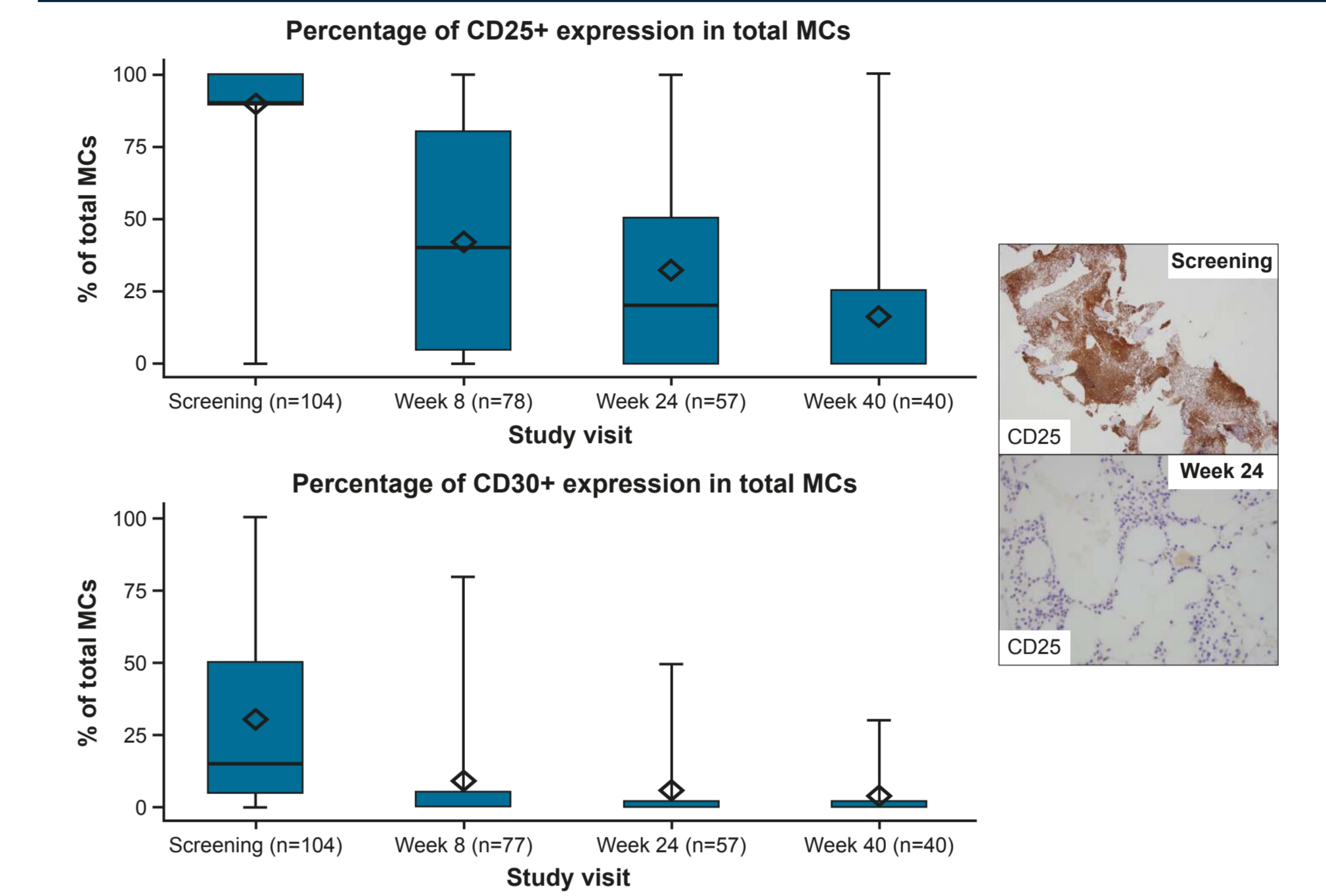
**Figure 5. Avapritinib decreased MCs and atypical morphology (immature and spindle shaped MCs) in BMAs by Week 8**



BMA, bone marrow aspirate; MC, mast cell; SM-MDS-RS, systemic mastocytosis-myelodysplastic syndrome-with ring sideroblast. Data shown in box and whisker plots explained in Figure 4.

- The mean percentage of total MCs in BMAs decreased from 10.5% at screening to 2.5% by Week 8
- Of 7 patients with circulating MCs at screening and post-screening sample measurements (6 with SM-AHN diagnoses and 1 with MCL), all 7 had no detectable MCs by Week 8

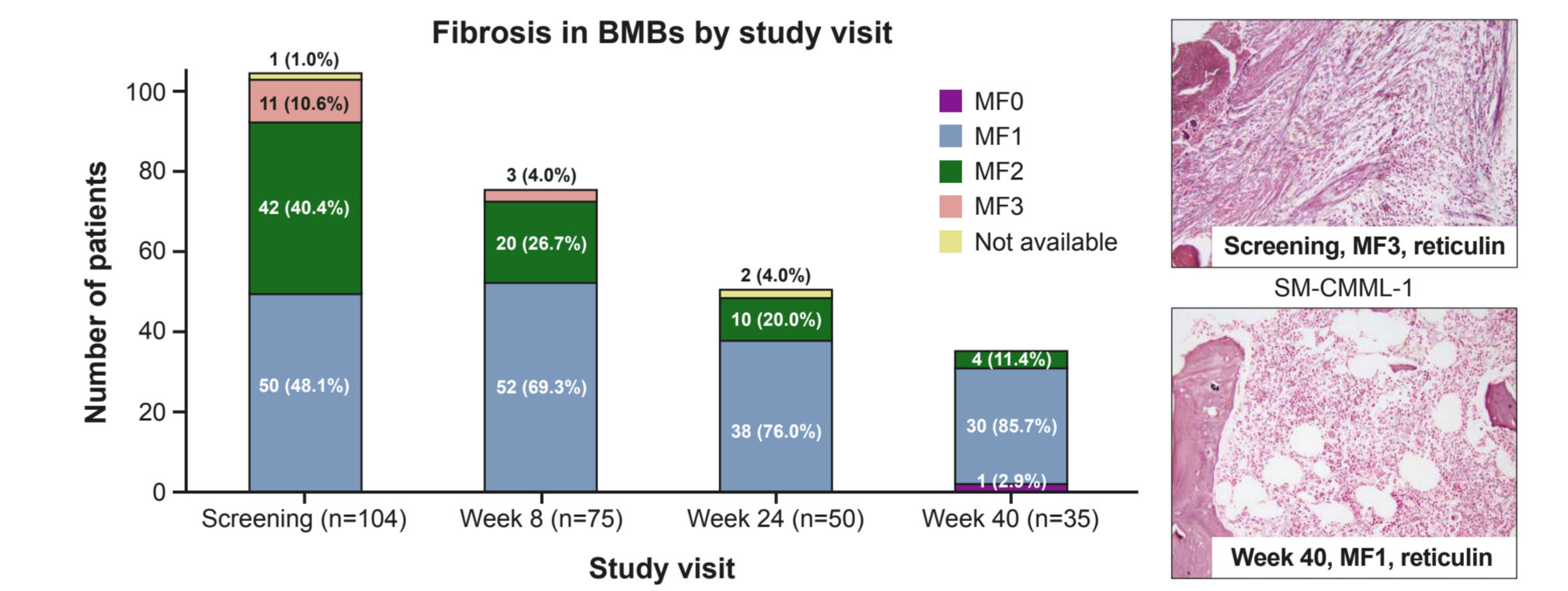
**Figure 6. Reduction in the proportion of CD25+ and CD30+ MCs by Week 8**



BMs, bone marrow biopsies; MC, mast cell. Data shown in box and whisker plots explained in Figure 4.

- The proportion of CD25+ in BMs decreased from a mean of 90.0% at screening to 41.5% by Week 8 and 32.3% by Week 24
- The proportion of CD30+ in BMs decreased from a mean of 30.6% at screening to 8.6% by Week 8

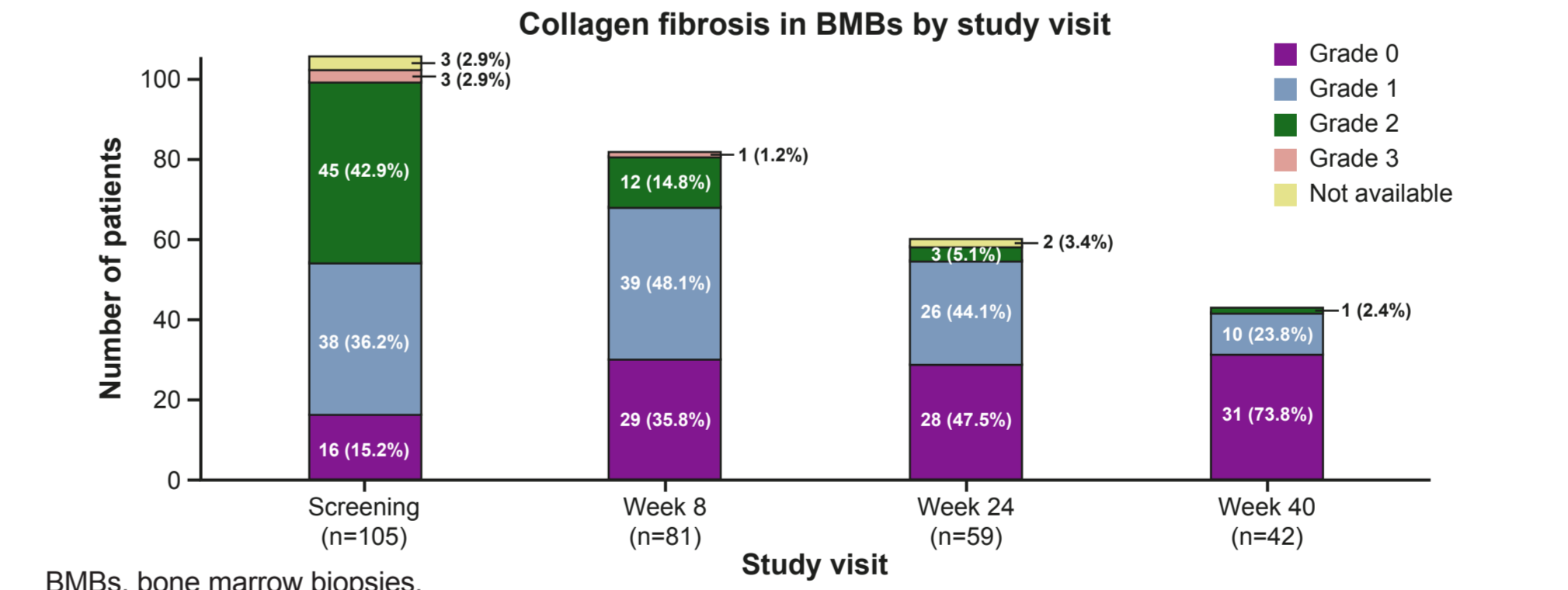
**Figure 7. Fibrosis decreased in BMs by Week 8**



BMs, bone marrow biopsies; MF, myelofibrosis; SM-CMML, systemic mastocytosis-chronic myelomonocytic leukemia.

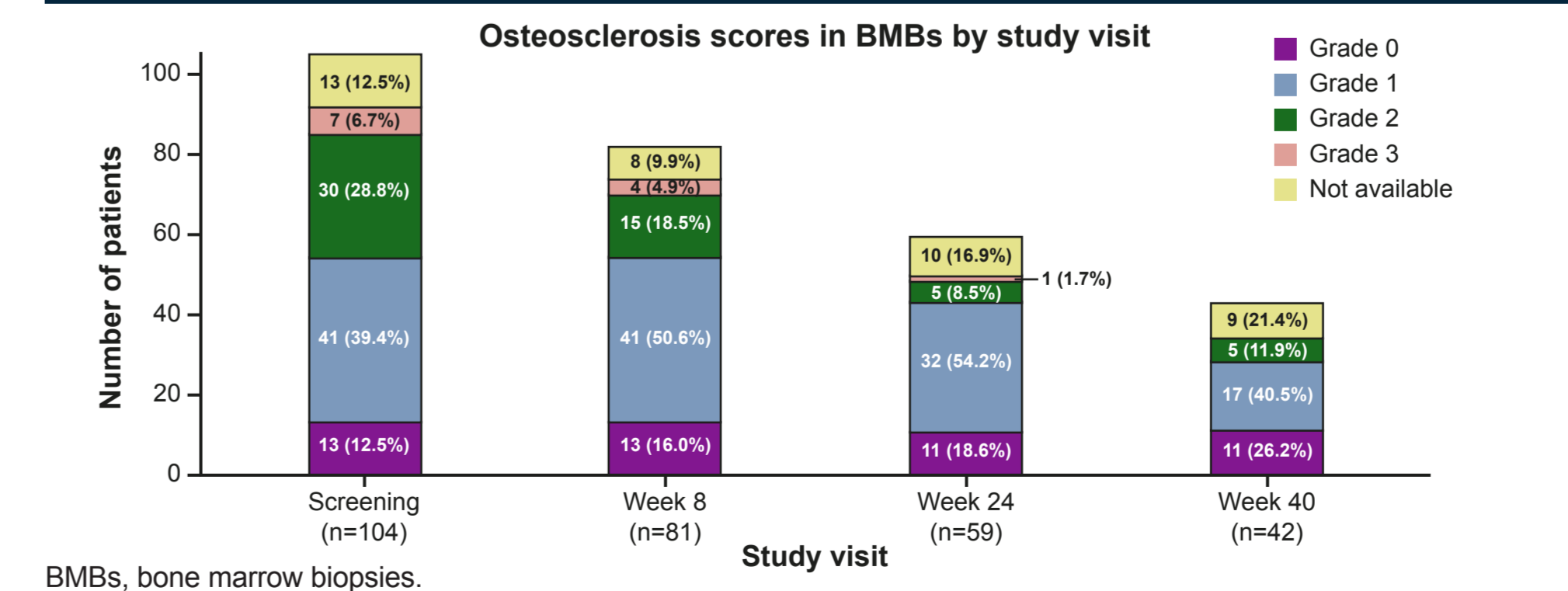
- Fibrosis was present in BMs in 99.0% (103/104) of patients at screening, 92.6% (75/81) of patients at Week 8, and in 82.8% (48/58) of patients at Week 24
- Fibrosis was reduced during avapritinib treatment in those patients presenting with increased fibrosis at screening

**Figure 8. Collagen fibrosis in BMs decreased by Week 8 and 24**



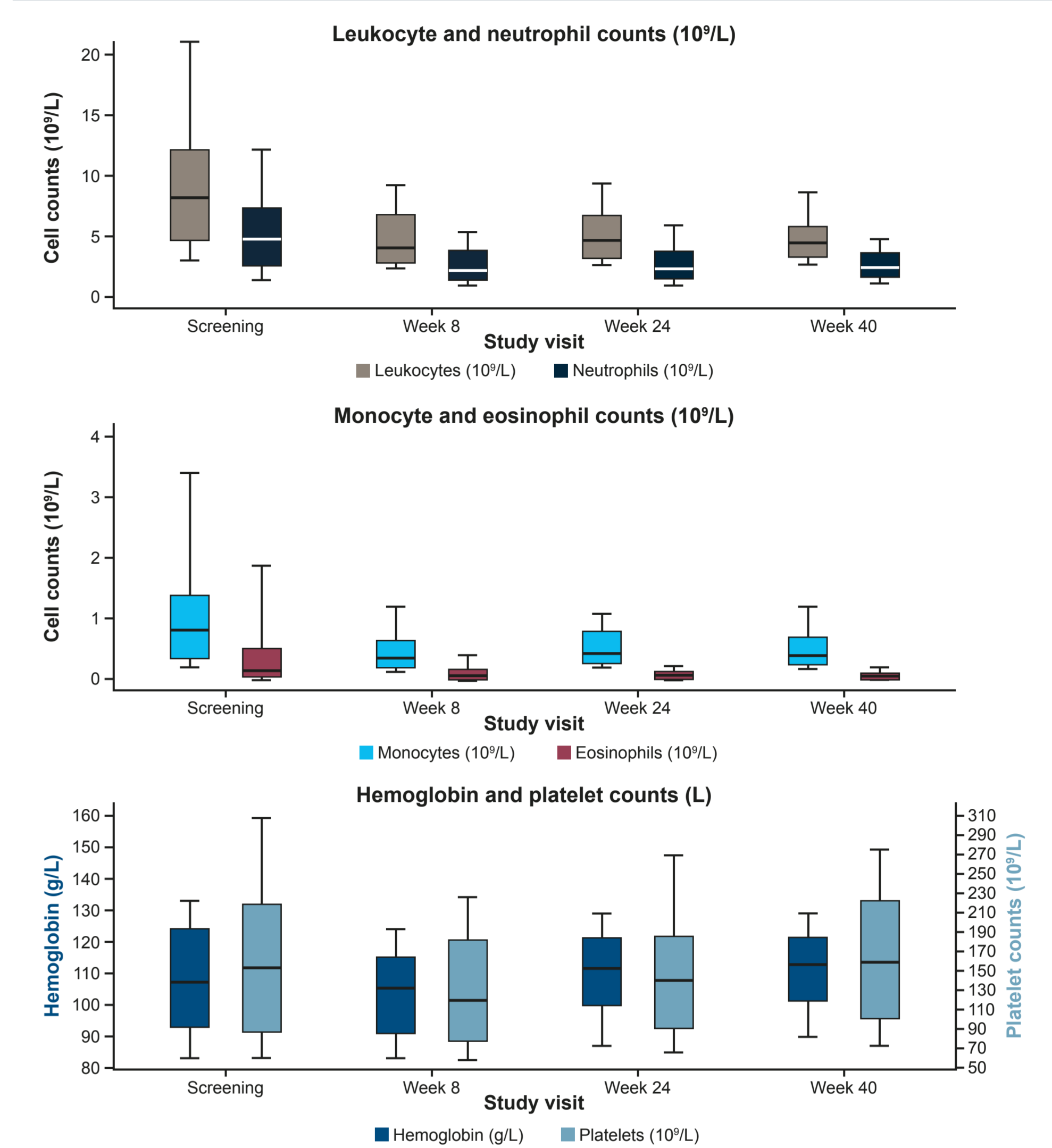
BMs, bone marrow biopsies.

**Figure 9. No significant changes in osteosclerosis scores were observed**



BMs, bone marrow biopsies.

**Figure 10. Changes in selected hematologic parameters in peripheral blood at screening, Weeks 8 and 24 (N=107)**



The box represents the middle (second - third quartile) of the data, the line within the box represents the median, and the whiskers represent the upper 75th to 90th percentiles and lower 10th to 25th percentiles.

- In peripheral blood, reductions in mean absolute leukocyte, neutrophil, monocyte, and eosinophil counts were observed by 8 weeks, while hemoglobin levels did not change significantly
- Platelets remained above 140x10<sup>9</sup>/L through Weeks 8 and 24

## Discussion

- The current findings, along with the previously reported high response rate with avapritinib,<sup>11-13</sup> support the clinical efficacy and provide proof of mechanistic concept for this highly selective and potent *KIT* D816V inhibitor
- High response rate was accompanied by a normalization of BM cellularity, as well as a decrease in fibrosis and marked improvement in hematologic parameters
- Avapritinib demonstrated rapid (Week 8) and sustained (Week 24) reductions in neoplastic MC burden characterized by a reduction of the total MC burden in BMs and BMAs with return to a normal morphologic appearance and normal immunophenotype
- These improvements in disease histopathology, along with known deep molecular remission of *KIT* D816V, suggest the potential for modification of the clinical course of AdvSM

## References

- Rossignol J et al. *Flt3* Research. 2019;8:1961. 2. Czorny J et al. *Adv Dermatol Allergol*. 2018;35:541-545. 3. Kristensen T et al. *J Mol Diagn*. 2011;13:180-188. 4. Reiter A et al. *Blood*. 2020;135:1365-1376. 5. Kristensen T et al. *Eur J Haematol*. 2016;96:381-388. 6. Arock M et al. *Leukemia*. 2015;29:1223-1232. 7. Horny HP et al. Chapter 3. Mastocytosis. In: Swerdlow SH et al, eds. *WHO Classification of Tumors of Hematopoietic and Lymphoid Tissues*. Lyon, France: International Agency for Research and Cancer (IARC); 2017:62-6. 8. Blatt K et al. *Blood*. 2015;126:2832-2841. 9. Pardisanani A. *Am J Hematol*. 2019;94:363-377. 10. AYAKIT™ (Avapritinib) Prescribing Information. June 2021. Blueprint Medicines Corporation. 11. DeAngelo D et al. *Nat Med EXPLORER* manuscript (to be updated). 12. Gotlib J et al. *Nat Med PATHFINDER* manuscript (to be updated). 13. Reiter A et al. Presented at: EHA 2021. Oral S201. 14. Thiele H et al. *Haematologica*. 2005;90:1128-1132. 15. Kvasnicka H et al. *Histopathology*. 2016;68:905-915.

## Acknowledgements

Medical writing support was provided by Deborah R. Cantu, PhD, and editorial support was provided by Travis Taylor, BA, all of Paragon, Knutsford, UK, supported by Blueprint Medicines Corporation, Cambridge, MA, according to Good Publication Practice guidelines.

## Disclosures

This research was funded by Blueprint Medicines Corporation. Blueprint Medicines Corporation reviewed and provided feedback on the poster. The authors had full editorial control of the poster and provided their final approval of all content. H-ML, JS, SD, and MF are employees of Blueprint Medicines Corporation; H-ML, JS, and SD hold equity interest in Blueprint Medicines Corporation. TIG is associated with ARUP Laboratories, owned by the University of Utah. TIG has received consulting fees from Blueprint Medicines Corporation, BMS, Celgene, and Inocyte, and has also served as consultant for Cogent but has received no fees. Full disclosures for all authors are available upon request at medinfo@blueprintmedicines.com

## Methods

- Peripheral blood smears, bone marrow biopsies (BMs), bone marrow aspirates (BMAs) and complete blood counts were obtained at screening and after approximately 8, 24, and 40 weeks